

Intramuscular Oxygen-Ozone Therapy in the Treatment of Acute Back Pain With Lumbar Disc Herniation

A Multicenter, Randomized, Double-Blind, Clinical Trial of Active and Simulated Lumbar Paravertebral Injection

Marco Paoloni, MD,*† Luca Di Sante, MD,*† Angelo Cacchio, MD,† Dario Apuzzo, MD,† Salvatore Marotta, MD,‡ Michele Razzano, MD,‡ Marianno Franzini, MD,§ and Valter Santilli, MD*†

Study Design. Multicenter randomized, double-blind, simulated therapy-controlled trial in a cohort of patients with acute low back pain (LBP) due to lumbar disc herniation (LDH).

Objective. To assess the benefit of intramuscular-paravertebral injections of an oxygen-ozone (O₂O₃) mixture.

Summary of Background Data. Recent findings have shown that O₂O₃ therapy can be used to treat LDH that fails to respond to conservative management. However, these findings are based on intradiscal/intraforaminal O₂O₃ injection, whereas intramuscular-paravertebral injection is the technique used most in clinical practice in Italy and other Western countries.

Methods. Sixty patients suffering from acute LBP caused by LDH was randomized to an intramuscular O₂O₃ or control group. Patients were observed up to assess pain intensity, LBP-related disability, and drug intake (15 [V2] and 30 [V3] days after treatment started, and 2 weeks [V4], and 3 [V5] and 6 [V6] months after treatment ended).

Results. A significant difference between the 2 groups in the percentage of cases who had become pain-free (61% vs. 33%, $P < 0.05$) was observed at V6. Patients who received O₂O₃ had a lower mean pain score than patients who received simulated therapy throughout the observation period. A significant improvement was observed in LBP-related disability in the study group patients when compared with the control group patients. Active O₂O₃ therapy was followed by a significantly lower number of days on nonsteroidal anti-inflammatory drugs at V2 and

V3 and by a lower number of days at V4. No adverse events were reported.

Conclusion. Treatment of LBP and sciatica is a major concern. Although the natural history of acute LBP is often self-limiting, conservative therapies are not always effective; in such cases, O₂O₃ intramuscular lumbar paravertebral injections, which are minimally invasive, seem to safely and effectively relieve pain, as well as reduce both disability and the intake of analgesic drugs.

Key words: acute low-back-pain, radiating pain, lumbar disc herniation, oxygen-ozone therapy. **Spine 2009; 34:1337–1344**

Acute low back pain (LBP) is a major cause of disability, including impairment in daily living activities and socioeconomic problems.^{1,2} Acute LBP is defined as pain that occurs posteriorly in the region between the lower rib margin and the proximal thighs that is of less than 6 weeks' duration.³ Radicular pain is defined as a pain that radiates below the knee whereas pseudoradicular pain does not go beyond the knee.⁴ Although the exact pathogenesis of acute LBP remains unclear, the prevalence of lumbar disc herniation (LDH) is estimated to be higher in patients with acute LBP than that in asymptomatic people (57% and 20%–28%, respectively).⁵ Although internal disc disruption remains a controversial issue,^{6,7} it has been suggested that this condition is a major cause of acute LBP.⁸ Indeed, internal disc disruption has been reported to be a cause in about 73% of cases of acute LBP⁹ and, when associated with LDH, as a cause in about 40% cases of radiating pain.¹⁰

Although the natural history of LDH tends to be favorable,^{11,12} relapses and recurrences are common, and low levels of pain and disability may persist in some patients.^{13–15}

Numerous therapeutic interventions for the treatment of LDH have been studied and performed, including noninvasive treatments, minimally invasive procedures, and surgery. It was recently demonstrated that back pain improved in intervertebral disc herniation patients treated both surgically and nonsurgically, though the degree of improvement was significantly greater in patients who underwent surgery; the difference between patients who underwent surgery and those who did not remaining statistically significant at 2 years.¹⁶ Relief from leg

From the *Physical Medicine and Rehabilitation Unit, Azienda Policlinico Umberto I, Rome, Italy; †Department of Orthopaedic Science, Board of Physical Medicine and Rehabilitation, University "La Sapienza," Rome, Italy; ‡CMR spa, Centro Medico di Diagnostica e Riabilitazione, Sant'Agata di Goti (BN), Italy; and §Italian Society of Oxygen-Ozone Therapy (SIOOT), Bergamo, Italy.

Acknowledgment date: June 12, 2008. First revision date: September 22, 2008. Second revision date: December 17, 2008. Acceptance date: December 19, 2008.

The device(s)/drug(s) is/are FDA-approved or approved by corresponding national agency for this indication.

Professional Organizational funds were received in support of this work. No benefits in any form have been or will be received from a commercial party related directly or indirectly to the subject of this manuscript.

Supported by the Italian Society of Oxygen-Ozone Therapy (SIOOT). The present research has been approved by the Ethics Committee for Human Experimentation of Azienda Policlinico Umberto I, Rome, Italy.

Address correspondence and reprint requests to Marco Paoloni, MD, Department of Orthopaedic Science, Piazzale Aldo Moro n.3, 00185 Rome, Italy; E-mail: paolonim@tin.it

pain was also greater in the surgically-treated group, and the degree of relief was greater than that reported for LBP.¹⁶

Minimally invasive treatments, such as percutaneous injections, a well-tolerated, low-cost procedure, have been shown to yield good clinical results,¹⁷ though no single treatment has yet proved to be clearly superior to any other.^{18–20}

Recent findings^{17,21–23} have shown that oxygen-ozone (O₂O₃) therapy can be used to treat LDH that fails to respond to conservative management, either before recourse to surgery or when surgery is not possible.

O₂O₃ therapy is used in medicine to treat various conditions^{24,25} and is based on the exploitation of the chemical properties of ozone (O₃), an unstable allotropic form of oxygen. In the treatment of LDH, O₂O₃ therapy has been proposed above all because it has: (i) a direct effect on the proteoglycans composing the disc's nucleus pulposus, which results in the release of water molecules and the subsequent cell degeneration of the matrix; this matrix is in turn replaced by fibrous tissue, which leads to a reduced disc volume²⁵; (ii) analgesic and anti-inflammatory effects, which may counteract disc-induced pain.^{17,25} As reported by Bonetti *et al*,²² a CT-guided intraforaminal infiltration of an O₂O₃ gas mixture seems to be as effective as periradicular steroid infiltrations in patients affected by chronic and acute LBP at the 1-week follow-up, while at the 6-month follow-up results are even better in patients with disc disease who receive O₂O₃ therapy than in those who receive steroid infiltrations.²² Moreover, intraforaminal and intradiscal injections of a combination of O₂O₃, steroids, and an anesthetic are more effective at 6 months than injections of a steroid and an anesthetic alone in the same sites in the management of radicular pain related to acute LDH.²³ According to Andreula *et al*,¹⁷ a combined intradiscal and periganglionic injection of medical O₃ and a periganglionic injection of steroids has a cumulative effect that enhances the overall outcome of treatment for pain caused by disc herniation.¹⁷

However, these findings are based on intradiscal/intraforaminal O₂O₃ injection, whereas intramuscular-paravertebral injection is the technique used most in clinical practice in Italy and other Western countries. For this reason, the Italian Public Health Ministry has recently encouraged scientific institution to promote clinical trials in this field. Otherwise on November 2006, the Istituto Superiore di Sanità, the leading technical and scientific public body of the Italian National Health Service, has promoted a Consensus Conference about lumbar paravertebral intramuscular injection of O₂O₃ in radicular pain caused by LDH, which results have been recently published.²⁶

To assess the short- and long-term impact of intramuscular-paravertebral O₂O₃ injection on acute LBP, we conducted a multicenter, randomized, double-blind, “simulated therapy”-controlled clinical trial in a cohort of patients with LDH. The aim of our trial was to assess

the benefit, if any, of O₂O₃ therapy as opposed to simulated injection in this target group, as expressed in terms of the number of pain-free patients at the end of treatment and treatment continuation.

■ Materials and Methods

Patients of both sexes aged between 18 and 65 years, seen between October 2004 and December 2006 in 3 medical rehabilitation centers in the North (Studio Medico Prof. Franzini, Bergamo, Italy), South (CMR spa, Centro Medico di Diagnostica e Riabilitazione, Sant'Agata di Goti [BN]), and center of Italy (Physical Medicine and Rehabilitation Unit, Azienda Policlinico Umberto I, Roma), were included if they reported acute LBP and/or radiating pain of moderate to severe intensity (≥ 5 on a 10-cm visual analog scale [VAS]) to one leg, and MRI evidence of disc protrusion with or without disc degeneration in the spinal segments involved in the pain. Acute LBP was defined as pain that occurs posteriorly in the region between the lower rib margin and the proximal thighs for less than 10 days in a patient who has been pain-free in the previous 3 months. Radiating pain was defined as pain, of less than 10 days' duration in a patient who has been pain-free in the previous 3 months, that radiates down the posterior or lateral part of the leg beyond the knee, with positive findings (reproduction of symptoms) at nerve tension tests (*i.e.*, straight leg raise or bow-string).

Local and radiating pain were assessed using a 10-cm horizontal VAS with 0 cm labeled “no pain” and 10 cm “worst pain I have ever had.” Subjects were asked to answer the question: “referring to the worst pain you have experienced in your life, what was the relative level of your back pain or radiating pain in the last week?” by placing a mark somewhere along the line.

Disc abnormalities were classified according to the Modic classification²⁷ and subjects with 4A herniated disc (protrusion with an intact anulus) were included in the study.

Exclusion criteria were: clinical signs of radiculopathy (*i.e.*, tendon reflex loss, myotomal weakness, sensory abnormalities); *cauda equina* syndrome, progressive neurologic deficit, and/or steppage due to complete L4–L5 damage, considered as lesions requiring surgery²⁸; lumbar stenosis; spondylolisthesis; previous spinal surgery; diabetic neuropathy; body mass index >30 ; lumbar scoliosis $>20^\circ$; lower limb length difference of more than 1.5 cm on plain radiographs; pregnancy; and favism, in which O₂O₃ therapy is contraindicated. Patients were also excluded if they had already received O₂O₃ therapy, to avoid a possible failure in the blinding procedure.

All the patients were orally informed of the potential risks of treatment as well as of the possibility of unknowingly receive simulated therapy. Written informed consent was obtained from all the subjects, and the procedures followed were approved by the Committee on Human Experimentation of the institutions involved.

Patients who met the eligibility criteria were randomized blindly to either the study group (SG) or control group (CG) using a computer-generated allocation sequence generated at the trial coordinating center. As soon as local investigators from the different centers enrolled patients, they informed the trial coordinating center by telephone to receive the assigned treatment group for each eligible patient.

On admission, every eligible patient was interviewed directly and given a complete physical examination and, where indicated, blood biochemical, hematological, electrophysiological

ical, and radiologic tests were performed. Data on pain (site, number of segments, aggravating factors), VAS scores, disability related to acute LBP, the patients' psychological profile, and quality of life were collected during the interview.

The Italian version of the Backill questionnaire,²⁹ which includes 27 functional questions and 4 questions qualifying the type of pain, was used to assess condition-specific pain and disability. The psychological profile was scored using the Italian translation of the Kellner rating scale.³⁰ The Italian version of the Rand 36-Item Health Survey (Short Form-36)³¹ was used to assess quality of life. MRI findings of disc protrusion were obtained on admission and verified at the 45-day follow-up using the same procedure and equipment. MRI examinations were read by the same radiologist in each center and disc protrusion changes were assessed using the Modic criteria.²⁷

Patients in the SG received 15 intramuscular infiltrations (3/wk for 5 consecutive weeks) of an O₂O₃ mixture (20 mL) with an O₃ concentration of 20 µg/mL, obtained by means of a Multiossigen PM95 generator (Multiossigen s.r.l., Gorle, Bergamo, Italy). The intramuscular injection was administered in the paraspinal lumbar muscles, bilaterally (10 mL for each side) using an extraspinal lateral approach, under sterile conditions, using a 22-gauge needle. The sites most frequently treated were those corresponding to L4–L5 (65%) and L5–S1 (25%). An injection time of 15 seconds was used, since a longer injection time was deemed unsuitable because of the instability of medical O₃, which starts decaying (2 µg/mL) after about 20 seconds. No premedication or anesthesia was given, and the procedure was performed in an outpatient clinic.

Patients in the CG received simulated treatment that lasted as long as the O₂O₃ treatment (15 infiltrations, 3/wk for 5 consecutive weeks). The simulated injection was administered using a false needle that pricked the skin without piercing it, applied at the lumbar paraspinal level, followed by hand-applied pressure on the same site designed to reproduce the load sensation commonly described after O₂O₃ injections.

To avoid possible blinding failure, the injection site in patients in both groups was covered with a water-proof plaster that was removed by the treating physician before the subsequent treatment session.

Both the active and simulated treatments were administered by the same physician at each center, who had received formal training in O₂O₃ therapy. After admission, the patients received an ad hoc diary in which they were asked to record, throughout the observation period, the days of pain, any non-steroidal anti-inflammatory drugs prescriptions, including the dose and kind of prescription. No opiates, steroids, or physical methods (e.g., therapeutic exercise, traction, physical therapy) were allowed. Daily variations in pain were assessed by means of a 10-cm horizontal VAS with 0 cm labeled no pain and 10 cm worst pain I have ever had. Subjects were asked to answer the question: "referring to the worst pain you have experienced in your life, what was the relative level of your back pain or sciatica today?" and responded by placing a mark somewhere along the line. Patients were also assessed for pain (VAS) and for disability related to the LBP (Backill questionnaire) at the scheduled visits during the treatment period (15 [V2] and 30 [V3] days after treatment started) and after treatment ended (2 weeks [V4], and 3 [V5] and 6 [V6] months). The assessors who were different from the investigators who enrolled the participants, were blind to the assigned treatments.

The primary outcome measures were: (i) the number of patients who were pain-free at the end of treatment (pain-free

condition was defined as a VAS score ≤1) and (ii) treatment failure, which was defined by the number of patients who interrupted the treatment they had been assigned because of no benefit (no reduction in pain). Participants were free to interrupt or continue the assigned treatment depending on their impressions of improvement and satisfaction.

Secondary outcome measures included changes in the Backill questionnaire score at each follow-up, changes in the VAS score at each follow-up, the mean number of days on nonsteroidal anti-inflammatory drugs during the treatment period, and the number of cases in which MRI (at 45 days) revealed at least a reduction in disc protrusion.

Statistical Analysis

Statistical analysis was performed using the SSP 2.5 statistical package (Smith's Statistical Package, version 2.75, 2004, Gary Smith, Pomona College, Claremont, CA).

All primary and secondary outcome analyses were performed according to the principle of intention-to-treat. The intention-to-treat analysis was carried out according to a "worst-case-scenario" analysis: subjects who did not complete the treatment or had not undergone the posttreatment or final follow-up assessments were assigned a poor outcome, corresponding to the final average change recorded in the per-protocol completer population in the CG.³² The χ^2 or Fisher exact test, Student *t* test or the Mann-Whitney *U* test, and analysis of variance (ANOVA) were used, as appropriate. The choice of parametric or nonparametric tests was dictated by the results of a normality test. A 2-way ANOVA with group (treatment *vs.* control) as the between-subjects factor and time as the within-subjects factor was used to assess the presence of significant differences between the SG and CG and within each group before and after treatment and at the 6-month follow-up. A Tukey *post hoc* comparison was used to identify significant differences between mean values when a significant main effect and interaction were found. For all analyses, the level of significance was set at $P < 0.01$.

Sample size was calculated under the assumption that 20% of patients randomized to simulated therapy and 55% of those randomized to O₂O₃ would be pain-free at the end of the treatment. On this basis, the minimum number of patients to be enrolled in each treatment arm would be 23 with at least 80% of power and 5% significance.

Results

During the study period, 327 outpatients with at least moderate acute LBP were seen at the study centers. Of these, 267 were not randomized because they were either ineligible ($n = 225$) or because they declined the invitation to participate ($n = 42$) (Figure 1). A total of 60 patients were randomized to either the SG ($n = 36$) or CG ($n = 24$). Table 1 summarizes the patients' main clinical features. The 2 treatment groups were fairly well-balanced as regards pain intensity.

At the end of follow-up, there was a significant difference between the SG and CG in the percentage of cases who had become pain-free (61% *vs.* 33%, $P < 0.01$) (Table 2).

Six patients (SG: 2 [5.6%]; CG: 4 [16.7%]) interrupted the treatment before the end of the study period because of unsatisfactory results (Figure 1).

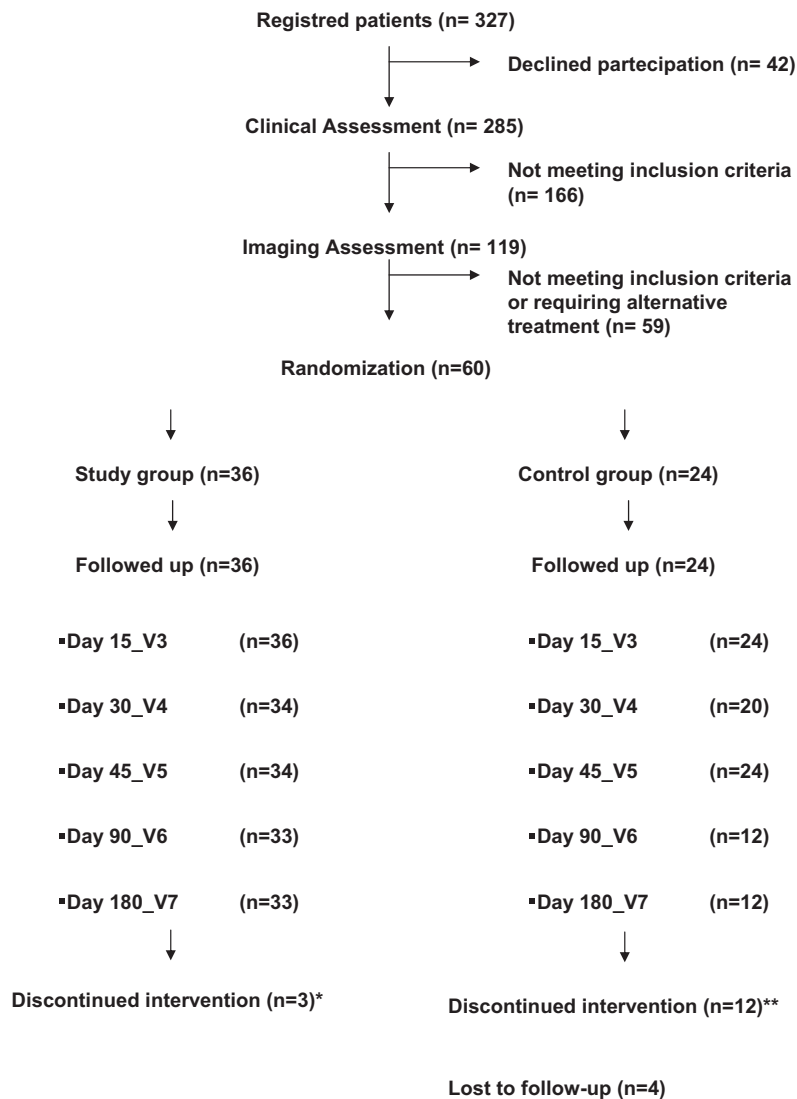


Figure 1. Flow diagram of the study.

* Lack of efficacy (n=3)
 **Lack of efficacy (n=12)

Patients who received O₂O₃ had a lower mean VAS score at V2 than the patients who received simulated therapy (mean difference 1.5) (Figure 2). The mean difference increased slightly at the subsequent visits, the

peak (2.3) being reached at V6. These differences were significant at the 2-way ANOVA (F: 43,390; P < 0.0001).

Table 1. Patient's Main Clinical Features

Variable	Study Group		Control Group	
	n	%	n	%
Total	36	100	24	100
Sex				
Male	18	50	10	41.6
Pain				
Lumbar	12	33.3	8	33.3
Radiating pain–left leg	12	33.3	10	41.6
Radiating pain–right leg	12	33.3	6	25
	Mean	SD	Mean	SD
Age (yr)	48.8	13.6	47.2	11.9
VAS*	7.74	0.66	7.33	1.25
Backill†	26	5.1	24.5	6.8

*VAS at baseline (V1).

†Backill questionnaire score at baseline (V1).

A significant improvement was observed in the Backill scores in the SG patients, when compared with the CG patients, at V3, V4, V5, and V6 (mean difference 3.6, 7.6, 10.3, and 8.9, respectively) (Figure 3). An improvement was observed in the Backill scores between the baseline and final follow-up in both groups (SG: +13.0; CG: + 5.6), but reached significance in the SG alone.

Active O₂O₃ therapy was followed by a significantly lower number of days on nonsteroidal anti-inflammatory drugs at V2 and V3 and by a lower (though not significant) number of days at V4. No drug intake was reported at V5 and V6 (Table 2).

There were no statistically significant differences in the Kellner symptom scores and SF-36 scores between groups (Table 3). Follow-up MRI findings were unchanged from baseline for all the patients in both groups. No adverse events were reported.

Table 2. Number (and Relative Percentage) of Patients Becoming Pain Free at Each Follow-up and Mean Days (and Standard Deviation) of Drug Assumption at Each Follow-up for Patients of Both Groups

Variable	Study Group		Control Group		P*
	n	%	n	%	
Patients becoming pain free (VAS)					
V2	0	0	0	0	NS
V3	2	5.6	0	0	NS
V4	4	11.1	0	0	NS
V5	14	38.9	2	8.3	<0.01†
V6	22	61.1	8	33.3	<0.01†
	Mean(SD)		Mean (SD)		P*
Drug assumption, no. d					
V2	2.56 (2.76)		5.33 (1.78)		<0.01‡
V3	1.20 (1.41)		4.40 (2.67)		<0.001‡
V4	0.67 (1.78)		2.83 (2.87)		NS
V5	0		0		NS
V6	0		0		NS

*Between group differences.
 †Fisher exact test.
 ‡Mann-Whitney U test.
 NS indicates not significant.

■ Discussion

The results of our study show that paravertebral intramuscular O₂O₃ injections, when compared with simulated therapy, afford greater pain relief, as demonstrated by higher number of pain-free subjects at the final follow-up examination in the SG, and reduce drug intake in people affected by acute LBP and/or radiating pain caused by LDH. This reduction in pain is reflected not only in a significant improvement in the Backill questionnaire score, which points to a reduced perception of LBP-related disability, but also in the significantly lower patient drop-out rate because of persisting pain during the treatment period.

These observations are not, however, accompanied by MRI changes in disc abnormalities. It should, nevertheless, be pointed out that the pathophysiology of LBP and radicular pain has not yet been fully understood.³³ Indeed, the mechanical effect of nerve root compression does not seem to completely explain radicular pain.³⁴ Inflammatory changes have been observed in lumbar disc and periradicular tissues in people suffering from lumbar and radiating pain,³⁵⁻³⁸ and a correlation has been found between inflammatory changes in herniated lumbar disc specimen and outcome after lumbar disc surgery, with a lower VAS rating in those patients showing inflammatory changes in the herniated disc after surgery.³³

Both chronic compression and the antigenic properties of the nucleus pulposus are presumable causes of the inflammatory reaction. Given the inclusion criteria adopted in our study, in which only subjects with a Modic²⁷ 4A stage of herniated disc (protrusion with an intact anulus) were considered, we may assume that the inflammatory pain in our patients was due mostly to chronic mechanical compression, rather than to an immune reaction against the nucleus pulposus. Consequently, the possible mechanism of action of the O₂O₃ mixture may be found in the biochemical properties of O₃. Indeed, numerous biologic effects have been attributed to this unstable allotropic form of oxygen, including an immunomodulating action³⁹ and analgesic and anti-inflammatory effects.^{25,40} This action is correlated with: (i) the inhibited synthesis of proinflammatory prostaglandins, the release of bradykinin, or the release of algogenic compounds; (ii) the increased release of antagonists or soluble receptors that neutralize proinflammatory cytokines, such as interleukin (IL)-1, IL-2, IL-8, IL-12, IL-15, interferon- α , and tumor necrosis factor- α (TNF- α); (iii) the increased release of immunosuppressor cytokines, such as transforming growth factor- β 1 and IL-10.^{25,40}

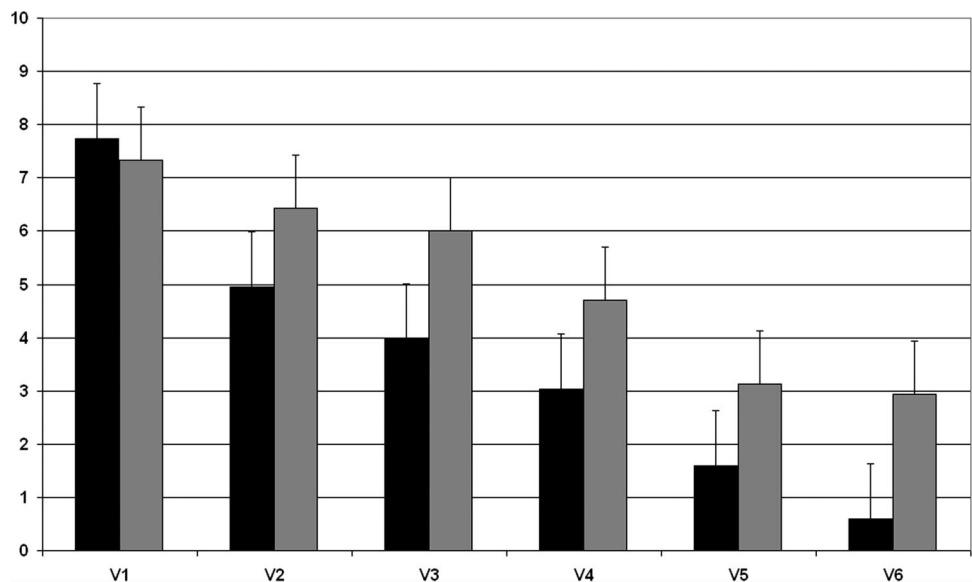


Figure 2. Mean VAS scores at different follow-up in SG (black bars) and CG (gray bars). Lower values correspond to clinical improvement.

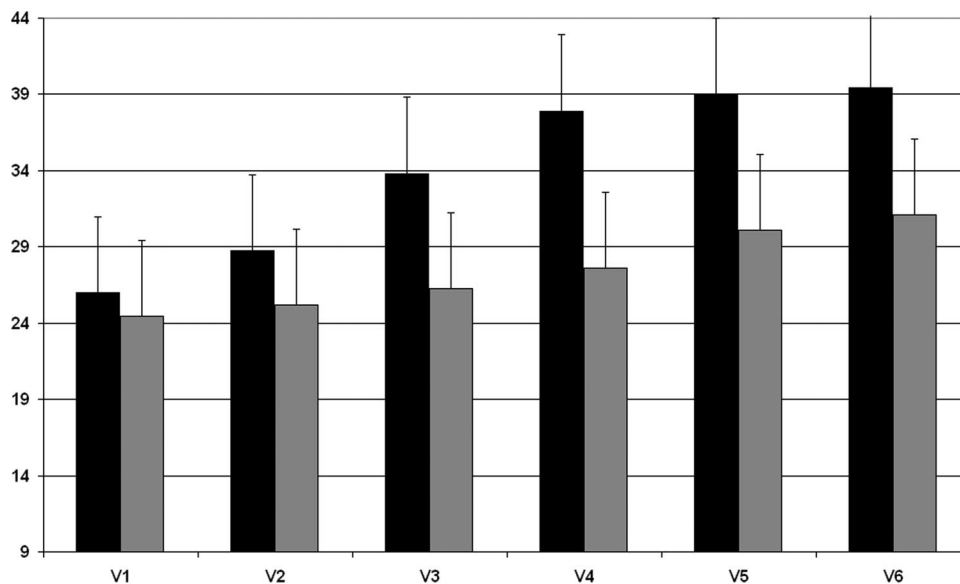


Figure 3. Mean Backill scores at different follow-up in SG (black bars) and CG (gray bars). Higher values correspond to clinical improvement.

In our patients, an O_3 concentration of $20 \mu\text{g/mL}$ was used to avoid the risk of toxicity. Indeed, O_3 concentrations $>60 \mu\text{g/mL}$ potentially exceed the capacity of antioxidant enzymes (superoxide dismutase and catalase) and glutathione to prevent accumulation of the superoxide anion (O_2^-) and hydrogen peroxide (H_2O_2),⁴¹ which can cause cell membrane degradation.⁴²

No adverse events were observed in our series in either the SG or CG. A case of fatal septic shock after intramuscular-paravertebral O_2O_3 injection was recently reported in one study.⁴³ The authors of that study sug-

gested that acute fatal septicemia should be considered as one of the possible major complications of O_2O_3 therapy in the treatment of a LDH. However, secondary septicemia after an invasive maneuver should be considered as a complication due to an inadequate asepsis procedure. Because we administered the therapy using a sterile procedure, every precaution was taken to avoid the risk of infection at the injection site.

Our results are only slightly inferior to those presented by Bonetti *et al*,²² who found, after studying 306 patients randomly treated with either a CT-guided intraforaminal infiltration of O_2O_3 or periradicular steroid infiltrations, that 84% and 74% of patients treated with O_2O_3 were pain-free respectively at the 1-week and 6-month follow-ups. However, since those authors included patients with both chronic and acute LBP, our results may only be partly comparable. Moreover, no mention was made by those authors of disability caused by LBP, which, in our experience, strongly influences the clinical outcome.

At the 6-month follow-up, our results seem to be comparable, in terms of pain reduction, disability, and drug consumption, to those obtained by means of a combined intradiscal and periganglionic injection of medical O_3 and a periganglionic injection of steroids.¹⁷

Some concern still surrounds exactly how the gas mixture is distributed after the injection. As we did not perform a pre/post MRI control, we could not study whether the O_2O_3 mixture reached the periradicular space. However, since the MRI findings were not modified at the 45-day follow-up, one may speculate that the action of O_2O_3 is exerted above all on the molecular inflammatory aspects of LBP and radicular pain, and not mechanically on root compression by the protruded lumbar disc. Indeed, as demonstrated by Igarashi *et al*,⁴⁴ facet joint tissues of patients with LDH display an increased level of inflammatory cytokines, though it remains lower than that of patients with lumbar degenerative disor-

Table 3. Quality of Life (SF-36 Health Survey) and Psychological Profile (Kellner Rating Score) of Patients of Both Groups at Baseline

	Study Group		Control Group	
	Mean	SD	Mean	SD
SF-36 health survey				
Domain				
Physical functioning	65.2	13.9	62.1	21.9
Role, physical	29.1	35.4	29.3	35.5
Bodily pain	31.8	10.3	31.8	12.6
General health	56.4	17.0	57.6	18.3
Vitality	55.7	14.1	54.4	15.2
Social functioning	56.2	12.7	54.0	14.4
Role, emotional	45.1	42.8	42.8	39.7
Mental health	73.5	13.9	70.2	11.7
Kellner rating scale				
Item				
Anxiety	6.2	2.6	6.0	2.8
Anxiety symptoms	3.3	2.3	3.5	1.9
Relaxed	2.4	1.6	2.5	1.6
Depression	4.0	3.1	4.0	2.8
Depression symptoms	2.0	1.9	2.2	1.4
Contented	2.1	1.7	2.2	1.6
Somatic	9.1	3.8	8.9	4.1
Somatic symptoms	5.3	3.2	5.3	4.2
Somatic well-being	4.4	1.7	4.3	1.5
Anger-hostility	3.5	2.9	3.3	2.6
Anger-hostility	2.1	2.5	2.2	2.4
Friendly	1.1	1.1	1.2	1.3

ders.⁴⁴ It could thus be speculated that inflammation of facet joints accounts for part of the pain in lumbar disorders, even when associated with LDH. From this point of view, the O₂O₃ injection at a paraspinal level may act as local antiphlogistic therapy.

One study recently demonstrated that nerve root compression may lead to morphologic changes in the dorsal horn of the lumbar cord.⁴⁵ The authors of that study speculate that nerve root compression disrupts the axonal flow in the nerve fibers of the dorsal root, which in turn causes Wallerian degeneration.⁴⁵ Assuming that this is true, the O₂O₃ mixture may even exert its effects far from its application site on account of its antiphlogistic properties, which would improve axonal function. In particular, since TNF- α seems to play a key role in inducing apoptosis of dorsal root ganglion cells,⁴⁶ the antagonistic effect exerted by the O₂O₃ mixture on TNF- α ^{25,40} may play an important protective role.

Another possible explanation for the therapeutic effect of injections may be a direct effect of the injection procedure on trigger points in the paraspinal musculature. Indeed, dry needling of trigger points has been shown to relieve pain in patients with myofascial pain syndrome, even if to a lesser degree than a lidocaine injection.⁴⁷ However, since myofascial pain syndrome patients more typically present neck pain or shoulder girdle pain, as opposed to LBP, we believe that trigger points are less likely to have had such an effect on acute LBP in our sample. Consequently, the therapeutic effect we observed is more likely to be due to the properties of the O₂O₃ mixture than to the needling itself.

The main limitation of this study is the possible failure of the blinding procedure. Because we did not conduct an exit interview designed to investigate the patients' perceptions of the therapy they had received, we cannot exclude the occurrence of unmasking. However, we attempted to reduce the possibility of blinding failure by excluding patients who had previously received O₂O₃ infiltrations and by masking the injection site.

As the external validity of our results is limited by the fact that only LBP with disc protrusion was considered, the findings need to be verified by replicating the study in other settings. Moreover, only patients who had been pain-free in the previous 3 months were included in our study; this means that we may have included some patients affected by recurrent LBP, *i.e.*, recurring episodes of acute LBP with pain-free intervals of more than 3 months. It should be borne in mind that this may have biased our results because of the differences in the natural history of these conditions. However, the fact that the natural history of a first episode of acute LBP is generally more favorable than that of recurrent LBP might have resulted in a worsening effect on the clinical outcomes of our patients.

The action of the O₂O₃ mixture may be reduced by the rapid decay to which it is subject. However, we believe that this drawback can be avoided by injecting

the gas shortly after it is produced, as specified in our protocol.

Lastly, as no cost-effectiveness analysis was performed in our study, no conclusions can be drawn in this regard; it should, however, be pointed out that this minimally invasive procedure can be performed, as it was in this study, in an outpatient clinic without any radiologic armamentarium, and is thus a relatively inexpensive form of therapy.

■ Conclusion

Treatment of acute LBP with or without radiating pain is a major concern. Although the natural history of acute LBP is often self-limiting, conservative therapies are not always effective; in such cases, O₂O₃ intramuscular lumbar paravertebral injections, which are minimally invasive, seem to safely and effectively relieve pain, as well as reduce both disability and the intake of analgesic drugs.

■ Key Points

- Minimally invasive treatments for acute LBP, such as percutaneous injections, offer good clinical results combined with a well-tolerated, low-cost procedure.
- O₂O₃ intramuscular lumbar paravertebral injections seem to safely and effectively relieve acute LBP with or without radiating pain, as well as reduce both disability and the intake of analgesic drugs.
- The possible mechanism of action of the O₂O₃ mixture may be found in the biochemical properties of O₃, which shows an immunomodulating action, and analgesic and anti-inflammatory effects.

References

1. Hart LG, Deyo RA, Cherkin DC. Physician office visits for low back pain. Frequency, clinical evaluation, and treatment patterns from a US national survey. *Spine* 1995;20:11–9.
2. van Tulder M, Koes B, Bombardier C. Low back pain. *Best Pract Res Clin Rheumatol* 2002;16:761–75.
3. van Tulder MW, Waddell G. Evidence-based medicine for nonspecific low back pain. *Best Pract Res Clin Rheumatol* 2005;19:vii–ix.
4. Freynhagen R, Rolke R, Baron R, et al. Pseudoradicular and radicular low-back pain—a disease continuum rather than different entities? Answers from quantitative sensory testing. *Pain* 2008;135:65–74.
5. Modic MT, Obuchowski NA, Ross JS, et al. Acute Low Back Pain and Radiculopathy: MR Imaging findings and their prognostic role and effect on outcome. *Radiology* 2005;237:597–604.
6. Lee KS, Doh JW, Bae HG, et al. Diagnostic criteria for the clinical syndrome of internal disc disruption: are they reliable? *Br J Neurosurg* 2003;17:19–23.
7. Carragee EJ, Alamin TF, Carragee JM. Low-pressure positive discography in subjects asymptomatic of significant low back pain illness. *Spine* 2006;31:505–9.
8. Crock HV. Internal disc disruption: a challenge to disc prolapse fifty years on. *Spine* 1986;11:650–3.
9. Hyodo H, Sato T, Sasaki H, et al. Discogenic pain in acute nonspecific low-back pain. *Eur Spine J* 2005;14:573–7.
10. Stevenson HO, Anderson GB. Low-back pain in 40-to 47-year-old men: work history and work environment factors. *Spine* 1983;8:272–6.
11. Saal JA, Saal JS. Nonoperative treatment of herniated lumbar intervertebral disc with radiculopathy: an outcome study. *Spine* 1989;14:431–7.

12. Weber H. The natural history of disc herniation and the influence of intervention. *Spine* 1994;19:2234–8.
13. Faas A, van Eijk JT, Chavannes AW, et al. A randomized trial of exercise therapy in patients with acute low back pain. Efficacy on sickness absence. *Spine* 1995;20:941–7.
14. Hazard RG, Haugh LD, Reid S, et al. Early prediction of chronic disability after occupational low back injury. *Spine* 1996;21:945–51.
15. Pengel LH, Herbert RD, Maher CG, et al. Acute low back pain: systematic review of its prognosis. *BMJ* 2003;327:3.
16. Pearson AM, Blood EA, Frymoyer JW, et al. SPORT lumbar intervertebral disk herniation and back pain: does treatment, location, or morphology matter? *Spine* 2008;33:428–35.
17. Andreula CF, Simonetti L, de Santis F, et al. Minimally invasive oxygen-ozone therapy for lumbar disk herniation. *Am J Neuroradiol* 2003;24:996–1000.
18. Spitzer WO, LeBlanc FE, Dupuis M. Scientific approach to the assessment and management of activity-related spinal disorders A monograph for clinicians. Report of the Quebec Task Force on Spinal Disorders. *Spine* 1987;12(suppl 7):S1–59.
19. van Tulder MW, Koes BW, Bouter LM. Conservative treatment of acute and chronic nonspecific low back pain: a systematic review of randomized controlled trials of the most common interventions. *Spine* 1997;22:2128–56.
20. Awad JN, Moskovich R. Lumbar disc herniations: surgical versus nonsurgical treatment. *Clin Orthop Rel Res* 2006;443:183–97.
21. Muto M, Andreula C, Leonardi M. Treatment of herniated lumbar disc by intradiscal and intraforaminal oxygen-ozone (O₂-O₃) injection. *J Neuroradiol* 2004;31:183–9.
22. Bonetti M, Fontana A, Cotticelli B, et al. Intraforaminal O₂-O₃ versus periradicular steroidal infiltrations in lower back pain: randomized controlled study. *Am J Neuroradiol* 2005;26:996–1000.
23. Gallucci M, Limbucci N, Zugaro L, et al. Sciatica: treatment with intradiscal and intraforaminal injections of steroids and oxygen-ozone versus steroid only. *Radiology* 2007;242:907–13.
24. Viebahn R. *The Use of Ozone in Medicine*. Heidelberg, Germany: Karl F. Haug; 1994.
25. Iliakis E, Valadakis V, Vynios DH, et al. Rationalization of the activity of medical ozone on intervertebral disc: a histological and biochemical study. *Riv Neuroradiol* 2001;14(suppl 1):23–30.
26. Coclite D, Napoletano A, Barbina D, et al, eds. *Conferenza di consenso. Ossigeno-ozono terapia nel trattamento delle lombosciatalgie da ernia discale con tecnica iniettiva intramuscolare paravertebrale*. Istituto Superiore di Sanità. Roma, 20 novembre 2006. Roma: Istituto Superiore di Sanità; 2008. (Rapporti ISTISAN 08/9). Available at: <http://www.iss.it/binary/publ/cont/08-9%20web.1208510331.pdf>.
27. Modic MT, Steinberg PM, Ross JS, et al. Degenerative disk disease: assessment of changes in vertebral body marrow with MR imaging. *Radiology* 1988;166:193–9.
28. Negrini S, Giovannoni S, Minozzi S, et al. Diagnostic therapeutic flow-charts for low back pain patients: the Italian clinical guidelines. *Eura Medicophys* 2006;42:151–70.
29. Tesio L, Granger CV, Fielder RC. A unidimensional pain/disability measure for low back pain syndromes. *Pain* 1997;69:269–78.
30. Kellner R. A symptom questionnaire. *J Clin Psychiatry* 1987;48:268–74.
31. Apolone G, Mosconi P, Ware JE Jr. *Questionario Sullo Stato di Salute SF-36. Manuale d'Uso e Guida Alla Interpretazione dei Risultati*. Milano, Italy: Guerini e associati SpA; 1997.
32. Hollis S, Campbell F. What is meant by intention-to-treat analysis? Survey of a published randomized controlled trials. *BMJ* 1999;319:670–4.
33. Woertgen C, Rothoerl RD, Brawanski A. Influence of macrophage infiltration of herniated lumbar disc tissue on outcome after lumbar disc surgery. *Spine* 2000;25:871–5.
34. Brown MD. The source of low back pain and sciatica. *Semin Arthritis Rheum* 1989;18(suppl 2):67–72.
35. Hirotsuka H, Shinomiya K, Komori H, et al. Upregulated expression of chemokines in herniated nucleus pulposus resorption. *Spine* 1996;21:1647–52.
36. Kawakami M, Tamaki T, Hashizume H, et al. The role of phospholipase A₂ and nitric oxide in pain-related behavior produced by an allograft of intervertebral disc material to the static nerve of the rat. *Spine* 1997;22:1074–9.
37. Kobayashi S, Baba H, Uchida K, et al. Effect of mechanical compression on the lumbar nerve root: localization and changes of intraradicular inflammatory cytokines, nitric oxide, and cyclooxygenase. *Spine* 2005;30:1699–705.
38. Siddall PJ, Cousins MJ. Spinal pain mechanisms. *Spine* 1997;22:98–104.
39. Bocci V. Autohaemotherapy after treatment of blood with ozone: a reappraisal. *J Int Med Res* 1994;22:131–44.
40. Bocci V, Luzzi E, Corradeschi F, et al. Studies on the biological effects of ozone: III, an attempt to define conditions for optimal induction of cytokines. *Lymphokine Cytokine Res* 1993;12:121–6.
41. Larini A, Bocci V. Effects of ozone on isolated peripheral blood mononuclear cells. *Toxicol In Vitro* 2005;19:55–61.
42. Bellomo G, Mirabelli F, Richelmi P, et al. Oxidative stress-induced plasma membrane blebbing and cytoskeletal alterations in normal and cancer cells. *Ann NY Acad Sci* 1989;551:128–30.
43. Gazzeri R, Galarza M, Neroni M, et al. Fulminating septicemia secondary to oxygen-ozone therapy for lumbar disc herniation: case report. *Spine* 2007;32:E121–3.
44. Igarashi A, Kikuchi S, Konno S, et al. Inflammatory cytokines released from the facet joint tissue in degenerative lumbar spinal disorders. *Spine* 2004;29:2091–5.
45. Kobayashi S, Uchida K, Kokubo Y, et al. Synapse involvement of the dorsal horn in experimental lumbar nerve root compression: a light and electron microscopic study. *Spine* 2008;33:716–23.
46. Murata Y, Nannmark U, Rydevik B, et al. The role of tumor necrosis factor- α in apoptosis of dorsal root ganglion cells induced by herniated nucleus pulposus in rats. *Spine* 2008;33:155–62.
47. Kamanli A, Kaya A, Ardicoglu O, et al. Comparison of lidocaine injection, botulinum toxin injection, and dry needling to trigger points in myofascial pain syndrome. *Rheumatol Int* 2005;25:604–11.